



doi:10.7659/j.issn.1005-6947.260106
http://dx.doi.org/10.7659/j.issn.1005-6947.260106
China Journal of General Surgery, 2026, 35(4):721-728.

· 胃肠外科专题研究 ·

腔内负压辅助闭合技术治疗食管空肠吻合口漏的疗效与安全性：21例回顾性分析（附视频）

邵国益^{1,2}, 薛徐夏¹, 仲卫冬^{1,2}, 赵振国², 胡根², 李家乐³, 华丽², 刘金春², 戴丽强², 王镇², 浦凌霄², 王苏睿³, 沈玥帆³, 耿良栋²

(1. 南通大学医学院, 江苏 江阴 214400; 2. 南通大学附属江阴医院/江苏省江阴市人民医院 普外一科, 江苏 江阴 214400; 3. 徐州医科大学江阴临床学院 普通外科, 江苏 江阴 214400)

摘要

背景与目的: 食管空肠吻合口漏是全胃切除术后严重并发症之一, 可导致腹腔及纵隔感染, 甚至危及生命。腔内负压辅助闭合 (EVAC) 技术近年来被应用于消化道漏的微创治疗, 但其在食管空肠吻合口漏中的临床证据仍有限。本研究旨在评估EVAC治疗食管空肠吻合口漏的临床疗效与安全性。

方法: 回顾性分析2022年1月—2025年7月江阴市人民医院采用EVAC治疗的21例食管空肠吻合口漏患者的临床资料。所有患者均经内镜或影像学确诊, 并在内镜引导下置入自制EVAC装置。观察技术成功率、漏口闭合率、EVAC治疗时间、漏口愈合时间、住院时间及治疗前后炎症指标变化, 并评估治疗相关并发症及长期随访结果。

结果: 21例患者均顺利完成EVAC置入及负压治疗, 技术成功率为100%。18例患者实现漏口闭合, 闭合率为85.7%。患者平均EVAC治疗时间为(15.8±8.2) d, 平均漏口愈合时间为(19.1±9.4) d, 中位住院时间为27 (25~49) d。治疗后白细胞计数及C-反应蛋白水平均较治疗前明显下降 (均 $P<0.05$)。治疗期间未发生消化道大出血、消化道狭窄、异物残留等严重并发症。平均随访(22.4±12.6)个月, 未见吻合口漏复发、消化道狭窄或新发脓肿形成。

结论: EVAC治疗食管空肠吻合口漏具有较高的技术成功率和漏口闭合率, 能够有效控制感染并促进漏口愈合, 且安全性良好, 可作为食管空肠吻合口漏的重要微创治疗选择。

关键词

胃切除术; 手术后并发症; 吻合口瘘; 腔内负压辅助闭合技术

中图分类号: R656.6

基金项目: 江苏省无锡市卫生健康委中青年拔尖人才基金资助项目 (HB2023102); 江苏省江阴市中青年卫生优秀人才基金资助项目 (JYROYT202301); 徐州医科大学附属医院发展基金资助项目 (XYFZ202302); 江苏省无锡市卫生健康委基金资助项目 (M202551); 江苏省无锡市卫生健康委科技成果和适宜技术推广基金资助项目 (T202548)。

收稿日期: 2026-02-26; **修订日期:** 2026-04-09。

作者简介: 邵国益, 南通大学医学院/南通大学附属江阴医院/江苏省江阴市人民医院主任医师, 主要从事胃肠道肿瘤以及腹腔重症感染方面的研究。

通信作者: 仲卫冬, Email: zwd4970@163.com

Efficacy and safety of endoluminal vacuum-assisted closure for esophagojejunal anastomotic leakage: a retrospective analysis of 21 cases (with video)

SHAO Guoyi^{1,2}, XUE Xuxia¹, ZHONG Weidong^{1,2}, ZHAO Zhenguo², HU Gen², LI Jiale³, HUA Li², LIU Jinchun², DAI Liqiang², WANG Zhen², PU Lingxiao², WANG Surui³, SHEN Yuefan³, GENG Liangdong²

(1. Medical School of Nantong University, Jiangyin, Jiangsu 214400, China; 2. Ward 1, Department of General Surgery, Affiliated Jiangyin Hospital of Nantong University/Jiangyin People's Hospital, Jiangyin, Jiangsu 214400, China; 3. Department of General Surgery, Jiangyin Clinical College of Xuzhou Medical University, Jiangyin, Jiangsu 214400, China)

Abstract

Background and Aims: Esophagojejunal anastomotic leakage is one of the most severe complications after total gastrectomy and may lead to intra-abdominal or mediastinal infection with high mortality. Endoluminal vacuum-assisted closure (EVAC) has recently emerged as a minimally invasive treatment for gastrointestinal leaks; however, evidence regarding its application in esophagojejunal anastomotic leakage remains limited. This study aimed to evaluate the efficacy and safety of EVAC in the treatment of esophagojejunal anastomotic leakage.

Methods: Clinical data of 21 patients with esophagojejunal anastomotic leakage treated with EVAC at Jiangyin People's Hospital between January 2022 and July 2025 were retrospectively analyzed. All patients were diagnosed by endoscopy or imaging examinations and underwent placement of a self-made EVAC device under endoscopic guidance. Technical success rate, fistula closure rate, duration of EVAC therapy, healing time, length of hospital stay, changes in inflammatory markers, treatment-related complications, and long-term outcomes were evaluated.

Results: All 21 patients successfully underwent EVAC placement and negative-pressure therapy, with a technical success rate of 100%. Fistula closure was achieved in 18 patients, yielding a closure rate of 85.7%. The mean duration of EVAC therapy was (15.8±8.2) d, and the mean healing time was (19.1±9.4) d. The median postoperative hospital stay was 27 (25–49) d. White blood cell count and C-reactive protein levels were significantly reduced after treatment compared with pre-treatment values (both $P < 0.05$). No severe treatment-related complications, including major gastrointestinal bleeding, stenosis, or foreign body retention, were observed. During a mean follow-up of (22.4±12.6) months, no recurrence of anastomotic leakage, gastrointestinal stenosis, or newly developed abscess was detected.

Conclusion: EVAC is an effective and safe minimally invasive treatment for esophagojejunal anastomotic leakage, with high technical success and fistula closure rates. It can effectively control infection and promote fistula healing, making it an important therapeutic option for this complication.

Key words

Gastrectomy; Postoperative Complications; Anastomotic Leak; Endoluminal Vacuum-Assisted Closure

CLC number: R656.6

食管空肠吻合口漏是胃切除术后最严重的并发症之一，可导致腹腔感染、纵隔感染、胸膜腔感染，甚至全身炎症反应综合征、感染性休克等，发生率通常在0.5%~14.6%之间，并伴有高相关病死率^[1-3]。长期以来，消化科医生一直致力于解决

食管空肠吻合口漏这一临床难题。传统治疗手段包括穿刺引流、外科手术等，近年来内镜技术在食管空肠吻合口漏中的应用越来越广泛，如覆膜支架、内镜吻合夹等^[4-5]。

腔内负压辅助闭合 (endoluminal vacuum-

assisted closure, EVAC) 技术作为一种创新的内镜下微创治疗手段, 目前被广泛应用于各种消化道漏, 如上消化道吻合口漏、食管破裂、结直肠吻合口漏、胰瘘、胆汁漏等^[6]。EVAC 技术在治疗食管空肠吻合口漏中的应用报道较少。本文总结江阴市人民医院综合普外科将EVAC技术用于治疗食管空肠吻合口漏的临床经验, 现报告如下。

1 资料与方法

1.1 一般资料

回顾性收集2022年1月—2025年7月在江阴市人民医院接受EVAC技术治疗的食管空肠吻合口漏患者的病例资料。纳入标准:(1)经内镜或影像学证实的食管空肠吻合口漏;(2)患者能够耐受内镜操作;(3)患者或家属同意接受EVAC技术治疗。排除标准:(1)合并支气管瘘;(2)存在严重的凝血功能障碍;(3)严重心肺功能不全, 不能耐受内镜

操作;(4)漏口周围有肿瘤残留;(5)漏口周围有大血管裸露;(6)聚氨酯海绵材料过敏。本研究已通过江阴市人民医院伦理委员会批准(批号:2026-KY011-01), 豁免患者知情同意。

1.2 方法

1.2.1 首次置入负压装置流程 内镜检查明确漏口位置和大小, 评估局部感染情况(图1A); 将导管预置入海绵中, 建立海绵中管道的潜在隧道, 将导管经鼻放入口咽部, 内镜引导下经口将导管引出(图1B-C); 将导管头端放入预制的圆柱状海绵中, 并将导管与海绵进行缝合固定(图1D); 内镜引导下, 使用抓钳抓住导管头端的线袢(图1E); 将EVAC装置放于漏口处使海绵覆盖漏口或将海绵经漏口放置于脓腔(图1F), 导管尾端连接负压装置, 提供-128 mmHg (1 mmHg=0.133 kPa) 负压。EVAC装置治疗食管空肠吻合口漏操作过程见视频1。

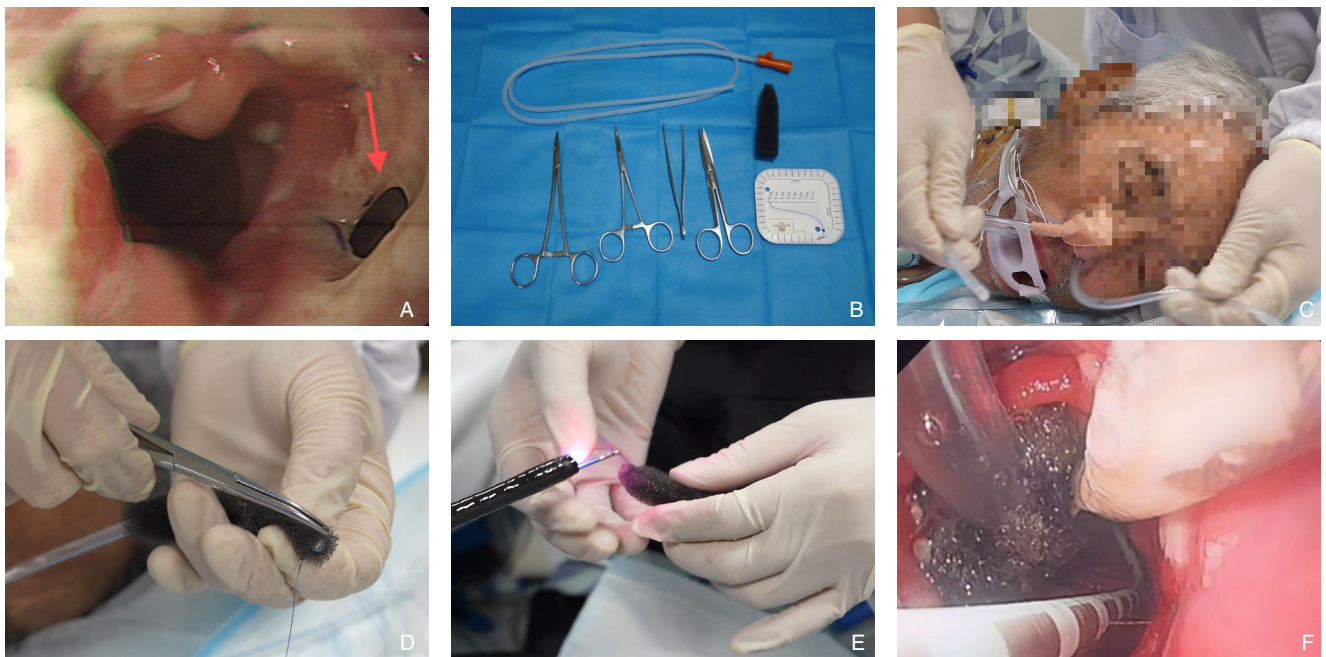


图1 EVAC装置治疗食管空肠吻合口漏术中图片 A: 内镜检查漏口位置和大小(红色箭头); B: 体外预制作EVAC装置; C: 经鼻将导管放置于口咽, 经口将导管头端拉出; D: 制作EVAC装置, 将导管和海绵缝合固定; E: 抓持海绵头端线袢; F: 内镜引导下将EVAC放置于消化道内跨越漏口

Figure 1 Intraoperative procedure of EVAC for esophagojejunal anastomotic leakage A: Endoscopic identification of the location and size of the fistula (red arrow); B: Extracorporeal preparation of the EVAC device; C: Placement of the catheter through the nasal cavity into the oropharynx with the distal end pulled out through the mouth; D: Assembly of the EVAC device by suturing the sponge to the catheter; E: Grasping the loop at the tip of the sponge; F: Endoscopic placement of the EVAC device across the fistula

食管空肠吻合口漏的平均愈合时间为 (19.1 ± 9.4) d。患者的中位住院时间为 27 (25~49) d。

2.3 安全性评价结果

在治疗过程中, EVAC 表现出较高的安全性, 治疗期间未观察到消化道大出血、消化道狭窄、异物残留等严重并发症, 1 例患者治疗期间肺部感

染加重。长期随访结局: 截至 2026 年 1 月 31 日末次随访, 平均随访 (22.4 ± 12.6) 个月, 未出现消化道狭窄、漏复发或新发脓肿, 提示 EVAC 具有持久的治疗效果。随访过程中有 5 例患者发现肿瘤复发、进展。

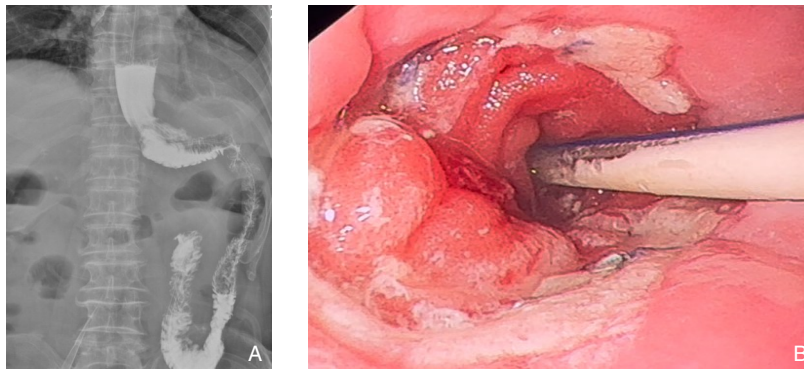


图2 EVAC 治疗后评估 A: 上消化道造影检查未见造影剂漏出; B: 通过内镜检查见漏口闭合

Figure 2 Post-treatment evaluation after EVAC therapy A: Upper gastrointestinal contrast study showing no contrast leakage; B: Endoscopic confirmation of fistula closure

3 讨论

本研究回顾性分析了 21 例接受 EVAC 技术治疗的食管空肠吻合口漏患者, 旨在评估该技术的临床有效性和安全性。结果显示, 本中心应用 EVAC 治疗食管空肠吻合口漏取得了显著的疗效, 85.7% 的患者实现了漏口的完全闭合, 且未发生严重的治疗相关并发症。结合当前文献, 笔者从 EVAC 作用机制、EVAC 的有效性、安全性、与其他技术的对比, 以及优势与局限等方面进行深入探讨。

3.1 EVAC 作用机制

EVAC 技术在治疗消化道漏中的作用机制是多方面的, 其核心在于通过施加可控的负压, 创造有利于组织愈合的微环境^[7] (图 3)。持续的负压吸引能够有效清除积聚在漏口及周围腔隙内的消化液、脓液和坏死组织, 主动引流不仅降低了局部细菌负荷, 同时减少了消化液对周围组织的侵蚀, 为愈合过程创造了相对清洁的创面^[8]。均匀分布的负压能够使漏口周围的软组织向中心靠拢, 产生机械性闭合力有助于促进漏口闭合^[9]。负压产生的机械应力对局部组织具有生物调节作用, 从而改善局部微循环, 增加血流灌注, 促进成纤维细胞

和内皮细胞的增殖与迁移, 最终促进漏口闭合^[10-11]。

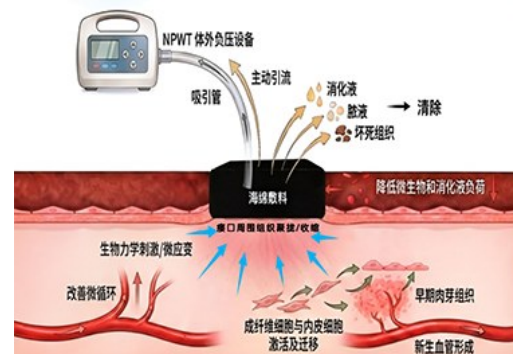


图3 EVAC 作用机制 (依据文献进行绘制)

Figure 3 Mechanisms of EVAC therapy (illustrated based on the literature)

3.2 EVAC 治疗的有效性

本研究中, 全部患者均成功接受 EVAC 治疗 1 次以上, 技术成功率 100%。经 EVAC 治疗后, 患者的白细胞和 C-反应蛋白等炎症指标明显降低, 提示患者的感染得到有效控制。经 EVAC 治疗的食管空肠吻合口漏闭合率达到 85.7%, 验证了 EVAC 在治疗食管空肠吻合口漏中的有效性。这与其他研究报道的 EVAC 治疗食管吻合口漏的闭合率

70%~90%相近^[12-19]，相较于传统保守治疗或单纯引流具有明显优势，且EVAC技术能够显著缩短漏口的闭合时间和患者的住院时间^[12,14]，同时降低了因消化道漏存在导致的营养不良、感染加重等风险，从而改善了患者的临床预后和生活质量^[14-15]。本研究中，平均15.8 d的治疗时间与文献^[20]报道的EVAC治疗吻合口漏的治疗时长相吻合，表明在掌握正确技术要点、营养支持等的前提下，EVAC能够在相对较短的时间内实现消化道漏的闭合^[21]。

3.3 EVAC治疗的安全性

安全性是评估新技术临床推广的关键指标。本研究中，EVAC治疗期间未发生消化道出血、异物残留等严重并发症，无患者因EVAC治疗导致死亡。这些结果初步证实了EVAC的操作安全性。虽然本研究未出现严重并发症，但文献报道中确实存在一定的风险。例如，德国Engelke等^[22]报道了EVAC治疗过程中可能出现的并发症，如消化道狭窄、海绵移位、创面出血以及血管侵蚀等。这些并发症中，消化道狭窄是最常见的，通常需要内镜下扩张或再次手术治疗^[23]。已有研究^[24]报道了因出血导致的死亡案例，临床医师在进行EVAC治疗时需严格筛选患者，评估血管解剖位置，避免在重要血管周围施加负压。

3.4 EVAC技术与其他内镜技术的对比

覆膜自膨式金属支架（self-expandable metal stent, SEMS）封堵技术是治疗消化道吻合口漏的传统且常用的内镜方法之一，通过内镜将覆膜支架输送至漏口位置释放、封闭漏口，同时维持消化道管腔的通畅^[25]。该技术操作相对简单，适用于早期、漏口较小且无大脓腔的情况^[26]。但是SEMS存在较高的支架移位和组织压力性坏死风险^[27-28]，且面临因肉芽组织嵌入支架而取出困难的风险^[26]，对于感染严重、脓腔较大的复杂性瘘，SEMS因无法有效引流脓腔而治疗效果不佳^[29]。

内镜下夹闭技术（over the scope clip, OTSC）是处理消化道漏口的重要微创手段，OTSC能抓取并闭合较大范围的组织^[30]，适用于组织新鲜、血供良好、边缘整齐的漏口^[4]。但其夹持力有限，对组织水肿或纤维化者易脱落、效果差，同样存在不能主动引流的缺陷，不适用于大的漏口和局部感染重的患者^[29,31]。

与传统的SEMS或OTSC技术相比，EVAC具有显著的优势^[5,32]。Riva等^[33]比较了采用SEMS和

EVAC治疗食管胃切除术后吻合口漏的效果（ $n=45$ ），结果显示，SEMS的成功率为86.4%，EVAC的成功率为95.6%；且EVAC的并发症发生率显著低于SEMS，SEMS治疗过程中发生支架移位率达到36.4%。虽然EVAC治疗的并发症少，且治疗时间短，但是治疗费用明显高于SEMS。因EVAC治疗需要定期更换装置，内镜操作和材料费用都明显增加。笔者团队通过自制EVAC装置，已将材料费用显著降低。临床上这些内镜技术都有其优势和合适的场景。总体来讲，SEMS和OTSC都适用于漏口相对较小、组织新鲜、周围感染相对较轻的情况；EVAC因其不但能够吸除脓液、清除坏死组织，而且能促进肉芽组织新生、利于漏口闭合，使用场景较广。

3.5 本研究的局限性和不足

尽管本研究得出了积极的结果，但仍存在一定的局限性。首先，本研究为单中心、回顾性研究，样本量较小，可能存在选择偏倚。其次，EVAC技术操作较为复杂，需要内镜医师具备丰富的经验。EVAC装置的置入增加了患者的不适感，仍需进一步优化改进该装置以提高患者舒适度和操作效率。尽管本研究随访中未见消化道狭窄或瘘的复发，但是迟发性并发症可能在更长时间的随访中出现，仍需进行更长期的随访观察。此外，本研究缺乏与SEMS或OTSC等其他内镜治疗方式的同期对照，尚无法明确EVAC在疗效及成本效益方面的相对优势。

综上所述，EVAC在治疗食管空肠吻合口漏中有显著的临床优势，其对感染的有效控制，对肉芽组织的诱导并促进漏口闭合、并发症发生率低，使其成为当前微创内镜治疗的首选方案之一。

作者贡献声明：邵国益负责提出设计方案、修改文章、指导临床实践、提供科研基金资助；薛徐夏负责病例随访、采集数据、统计分析；仲卫冬负责撰写文章、返修文章、监督研究并提供科研基金资助；赵振国、胡根、李家乐负责临床操作、病例随访、采集数据；华丽负责图片绘制；刘金春负责视频剪辑；戴丽强、王镇、浦凌霄、王苏睿负责病例随访、采集数据；沈玥帆、耿良栋负责文献检索。

利益冲突：所有作者均声明不存在利益冲突。

参考文献

- [1] 中华医学会外科学分会胃肠外科学组, 中国医师协会外科医师分会肿瘤外科医师委员会. 胃癌全胃切除术后食管空肠吻合口并发症防治中国专家共识(2020版)[J]. 中国实用外科杂志, 2021, 41(2): 121-124. doi: 10.19538/j.cjps.issn1005-2208.2021.02.01.
Chinese Society of Gastrointestinal Surgery, Chinese Society of Surgery, Chinese Medical Association, Surgical Oncology Committee of the Surgeon Branch in the Chinese College of Surgeons, Chinese Medical Doctor Association. Chinese expert consensus on the prevention and treatment of esophagojejunostomy complications after total gastrectomy for gastric cancer(2020 edition)[J]. Chinese Journal of Practical Surgery, 2021, 41(2): 121-124. doi:10.19538/j.cjps.issn1005-2208.2021.02.01.
- [2] Wang YF, Guo ZQ, Han JX, et al. Analysis of risk factors for esophagojejunal anastomotic leakage after total gastrectomy based on Bayesian network model[J]. Front Med (Lausanne), 2025, 12: 1632214. doi:10.3389/fmed.2025.1632214.
- [3] Liu J, Hu J, Fang J, et al. Risk factors of esophagojejunal anastomotic leakage after total gastrectomy for gastric and Siewert type II/III esophagogastric cancer: a retrospective analysis from a tertiary hospital[J]. Front Oncol, 2024, 14: 1481278. doi: 10.3389/fonc.2024.1481278.
- [4] 陈妍, 熊文俊, 郑燕生, 等. 胸腔内改良 Overlap 法在腹腔镜 Siewert II 型食管胃结合部腺癌手术中的应用价值[J]. 中华胃肠外科杂志, 2022, 25(2): 173-178. doi: 10.3760/cma.j.cn441530-20210222-00075.
Chen Y, Xiong WJ, Zheng YS, et al. Safety and feasibility of intrathoracic modified overlap esophagojejunostomy in laparoscopic radical resection of Siewert type II adenocarcinoma of esophagogastric junction[J]. Chinese Journal of Gastrointestinal Surgery, 2022, 25(2): 173-178. doi: 10.3760/cma.j.cn441530-20210222-00075.
- [5] 徐义军, 张文杰. 消化道吻合口瘘内镜微创治疗的现状及进展[J]. 中国普通外科杂志, 2019, 28(4): 491-497. doi: 10.7659/j.issn.1005-6947.2019.04.016.
Xu YJ, Zhang WJ. Endoscopic minimally invasive treatment of gastrointestinal anastomotic fistula: current status and progress[J]. China Journal of General Surgery, 2019, 28(4): 491-497. doi: 10.7659/j.issn.1005-6947.2019.04.016.
- [6] de Armas Conde M, Díaz-López C, Concepción-Martín V, et al. Endoscopic vacuum therapy: management of upper gastrointestinal anastomotic leaks and esophageal perforations[J]. Rev Esp Enferm Dig, 2024, 117:352-353. doi:10.17235/reed.2024.10424/2024.
- [7] Aziz M, Haghbin H, Sharma S, et al. Safety and effectiveness of endoluminal vacuum-assisted closure for esophageal defects: Systematic review and meta-analysis[J]. Endosc Int Open, 2021, 9(9):E1371-E1380. doi:10.1055/a-1508-5947.
- [8] Pepe G, Chiarello MM, Bianchi V, et al. Entero-cutaneous and entero-atmospheric fistulas: insights into management using negative pressure wound therapy[J]. J Clin Med, 2024, 13(5):1279. doi:10.3390/jcm13051279.
- [9] Moog P, Jensch M, Betzl J, et al. Bacterial bioburden of wounds: influence of debridement and negative-pressure wound therapy (NPWT)[J]. J Wound Care, 2021, 30(8): 604-611. doi: 10.12968/jowc.2021.30.8.604.
- [10] Wiegand C, White R. Microdeformation in wound healing[J]. Wound Repair Regen, 2013, 21(6):793-799. doi:10.1111/wrr.12111.
- [11] Vallejo-Carmona L. Structure-guided negative pressure wound therapy (NPWT): personalised tissue biomodulation with an NPWT system in adults and older adults[J]. J Wound Care, 2025, nn(S11e):S1-S23. doi:10.12968/jowc.2025.34.s11e.s1.
- [12] Zhong WD, Hu G, Feng ZH, et al. Endoluminal vacuum-assisted closure therapy for upper gastrointestinal leak, perforation, and fistula: a case series and literature review[J]. Dig Dis, 2023, 41(3): 506-512. doi:10.1159/000526713.
- [13] Schäfer C. Don't be afraid of black holes: Vacuum sponge and vacuum stent treatment of leaks in the upper GI tract: a case series and mini-review[J]. Front Surg, 2023, 10: 1168541. doi: 10.3389/fsurg.2023.1168541.
- [14] Rashed A, Fülöp J, Caicut L, et al. A negatív nyomású sebkezelés helye a modern sebészetben[J]. Orvosi Hetilap, 2022, 163(7):271-278. doi:10.1556/650.2022.32369.
- [15] 仲卫冬, 张永强, 胡根, 等. 腔内负压辅助闭合装置在消化道瘘治疗中的应用[J]. 中华胃肠外科杂志, 2023, 26(9):874-877. doi: 10.3760/cma.j.cn441530-20230608-00197.
Zhong WD, Zhang YQ, Hu G, et al. Application of endoluminal vacuum-assisted closure device in the treatment of gastrointestinal fistula[J]. Chinese Journal of Gastrointestinal Surgery, 2023, 26(9): 874-877. doi:10.3760/cma.j.cn441530-20230608-00197.
- [16] Jung CFM, Hallit R, Müller-Dornieden A, et al. Endoscopic internal drainage and low negative-pressure endoscopic vacuum therapy for anastomotic leaks after oncologic upper gastrointestinal surgery[J]. Endoscopy, 2022, 54(1): 71-74. doi: 0.1055/a-1375-8151.
- [17] Jung CFM, Müller-Dornieden A, Gaedcke J, et al. Impact of endoscopic vacuum therapy with low negative pressure for esophageal perforations and postoperative anastomotic esophageal leaks[J]. Digestion, 2021, 102(3):469-479. doi:10.1159/000506101.
- [18] Christogianni V, Ross M, Dukovska R, et al. Endoscopic negative pressure therapy for post-sleeve gastrectomy proximal staple-line

- leaks: a single-center experience of 40 patients[J]. *Dig Surg*, 2025, 42(3):97-104. doi:10.1159/000545177.
- [19] Vohra I, Gopakumar H, Sharma NR, et al. Efficacy of endoscopic vacuum therapy in esophageal luminal defects: a systematic review and meta-analysis[J]. *Clin Endosc*, 2025, 58(1):53-62. doi:10.5946/ce.2023.282.
- [20] Hayami M, Klevebro F, Tsekrekos A, et al. Endoscopic vacuum therapy for anastomotic leak after esophagectomy: a single-center's early experience[J]. *Dis Esophagus*, 2021, 34(9): doaa122. doi:10.1093/dote/daaa122.
- [21] 张敬柱, 李刚, 周晶, 等. 肠内营养联合“升阶梯”引流治疗急性坏死性胰腺炎并发十二指肠瘘的疗效分析[J]. *中国普通外科杂志*, 2024, 33(9): 1473-1480. doi: 10.7659/j. issn. 1005-6947.2024.09.014.
- Zhang JZ, Li G, Zhou J, et al. Analysis of the efficacy of enteral nutrition combined with step-up drainage in the treatment of acute necrotizing pancreatitis complicated by duodenal fistula[J]. *China Journal of General Surgery*, 2024, 33(9):1473-1480. doi:10.7659/j. issn.1005-6947.2024.09.014.
- [22] Book T, Engelke C, Wedemeyer J, et al. Endoscopic vacuum-assisted closure therapy for leakage of the lower gastrointestinal tract: multicenter experiences[J]. *Endosc Int Open*, 2023, 11(2): E212-E217. doi:10.1055/a-1990-0392.
- [23] Cwaliński J, Paszkowski J, Lorek F, et al. Minimally invasive treatment of postoperative fistulas, leakages, and perforations of the upper gastrointestinal tract: a single-center observational study[J]. *Videosurgery Other Miniinvasive Tech*, 2023, 18(4):655-664. doi:10.5114/wiitm.2023.133838.
- [24] Lussier G, Evans AJ, Houston I, et al. Compact arterial monitoring device use in resuscitative endovascular balloon occlusion of the aorta (REBOA): a simple validation study in swine[J]. *Cureus*, 2024, 16(10):e70789. doi:10.7759/cureus.70789.
- [25] Rogalski P, Swidnicka-Siergiejko A, Wasilica-Berger J, et al. Endoscopic management of leaks and fistulas after bariatric surgery: a systematic review and meta-analysis[J]. *Surg Endosc*, 2021, 35(3):1067-1087. doi:10.1007/s00464-020-07471-1.
- [26] Lim SG. Endoscopic treatments in perforation or fistula in upper gastrointestinal tract[J]. *Korean J Helicobacter Up Gastrointest Res*, 2024, 24(1):31-39. doi:10.7704/kjhugr.2024.0010.
- [27] Martins BC, Gregorio JM, Sueta RU, et al. Efficacy and safety of self-expanding metal stents in advanced esophageal cancer: a 12-year analysis in a referral center[J]. *Dis Esophagus*, 2025, 38(3): doaf039. doi:10.1093/dote/doaf039.
- [28] Chou IT, Yu FJ, Shih HY, et al. Risk factors of stent migration in esophageal cancer patients who underwent fully-covered self-expanding metal stents for malignant dysphagia or tracheoesophageal fistula[J]. *J Formos Med Assoc*, 2025, 124(5): 432-438. doi:10.1016/j.jfma.2024.05.014.
- [29] Chan SM, Auyeung KKY, Lam SF, et al. Current status in endoscopic management of upper gastrointestinal perforations, leaks and fistulas[J]. *Dig Endosc*, 2022, 34(1):43-62. doi:10.1111/den.14061.
- [30] Bartell N, Bittner K, Kaul V, et al. Clinical efficacy of the over-the-scope clip device: a systematic review[J]. *World J Gastroenterol*, 2020, 26(24):3495-3516. doi:10.3748/wjg.v26.i24.3495.
- [31] Tada N, Kobara H, Tashima T, et al. Outcomes of endoscopic intervention using over-the-scope clips for anastomotic leakage involving secondary fistula after gastrointestinal surgery: a Japanese multicenter case series[J]. *Diagnostics (Basel)*, 2023, 13(18):2997. doi:10.3390/diagnostics13182997.
- [32] Pines G, Bar I, Elami A, et al. Modified endoscopic vacuum therapy for nonhealing esophageal anastomotic leak: technique description and review of literature[J]. *J Laparoendosc Adv Surg Tech*, 2018, 28(1):33-40. doi:10.1089/lap.2017.0318.
- [33] Riva CG, Siboni S, Capuzzo M, et al. Stenting versus endoscopic vacuum therapy for anastomotic leakage after esophago-gastric surgery[J]. *J Clin Med*, 2025, 14(19): 7075. doi: 10.3390/jcm14197075.

(本文编辑 熊杨)

本文引用格式: 邵国益, 薛徐夏, 仲卫冬, 等. 腔内负压辅助闭合技术治疗食管空肠吻合口漏的疗效与安全性: 21例回顾性分析(附视频)[J]. *中国普通外科杂志*, 2026, 35(4): 721-728. doi: 10.7659/j. issn.1005-6947.260106

Cite this article as: Shao GY, Xue XX, Zhong WD, et al. Efficacy and safety of endoluminal vacuum-assisted closure for esophagojejunal anastomotic leakage: a retrospective analysis of 21 cases (with video) [J]. *Chin J Gen Surg*, 2026, 35(4): 721-728. doi: 10.7659/j. issn.1005-6947.260106